

Tomography For Electrical Impedance, An Alternative Method For Monitoring Joint Injuries

Tomografía por impedancia eléctrica, un método alternativo para monitorización de lesiones articulares

Tomografia de impedância elétrica, método alternativo para monitorar lesões articulares

Juan David Muñoz Sánchez¹
Víctor Hugo Mosquera Leyton²

Received: September 17th, 2019

Accepted: November 22th, 2019

Available: January 31th, 2020

How to cite this article:

J. D. Muñoz Sánchez, V. H. Mosquera Leyton, "Tomography For Electrical Impedance, An Alternative Method For Monitoring Joint Injuries," *Revista Ingeniería Solidaria*, vol. 16, no. 1, 2020.
doi: <https://doi.org/10.16925/2357-6014.2020.01.05>

Artículo de investigación. <https://doi.org/10.16925/2357-6014.2020.01.05>

¹ Electronic, Instrumentation and Control Department, University of Cauca.

ORCID: <https://orcid.org/0000-0001-6295-6778>

Email: juand@unicauca.edu.co

² Electronic, Instrumentation and Control Department, University of Cauca

ORCID: <https://orcid.org/0000-0003-4884-9719>

E-mail: mosquera@unicauca.edu.co

Abstract

Introduction: This review article shows the state of the art of different techniques for monitoring joint injuries. This work is the product of the research project "Viability of electrical impedance tomography for the monitoring of joint injuries", which took place at the University of Cauca during the period 2018-2019.

Aim: Identify non-invasive bio-image methods that are used in the evaluation of joint diseases.

Methodology: Selection and review of papers related to the evaluation of joint injuries using non-invasive bio-image technologies using systematic mapping.

Results: Magnetic resonance and computed tomography systems make up the non-invasive methods of greater reliability and application in the evaluation of joint injuries. Similarly, some studies show good results from other methods such as systems based on bio-impedance when monitoring the deterioration of joint cartilage. However, electrical impedance tomography (EIT) devices have not yet been widely studied in the joint injuries evaluation.

Conclusion: Electronic prototypes of low-cost electrical impedance tomography have been developed that have allowed for the detection and recognition of gestures made by hand from the analysis of the distribution of conductivity in the wrist joint, which allows us to infer that EIT could be a good alternative for the monitoring of joint injuries.

Originality: The literature does not show studies focused on the development and implementation of EIT systems in medical applications related to joint injuries.

Limitations: This review paper only mentions those studies that describe the non-invasive bio-image methods used to evaluate joint diseases, including the medical applications of EIT systems.

Keywords: Joint diseases, Joint monitoring, Bio-image, Bioimpedance, Electrical impedance tomography (EIT).

Resumen

Introducción: El artículo de revisión muestra el estado del arte de diferentes técnicas para el monitoreo de lesiones en las articulaciones, este trabajo es producto del proyecto de investigación "Viabilidad de la tomografía por impedancia eléctrica para la monitorización de lesiones articulares", que tiene lugar en la Universidad del Cauca durante el periodo 2018-2019.

Objetivo: Identificar los métodos de bioimágenes no invasivos que se utilizan en la evaluación de enfermedades articulares.

Metodología: Selección y revisión de artículos relacionados con la evaluación de lesiones articulares utilizando tecnologías de bioimágenes no invasivas mediante un mapeo sistemático.

Resultados: Los sistemas de resonancia magnética y tomografía computarizada constituyen los métodos no invasivos de mayor confiabilidad y aplicación en la evaluación de lesiones articulares. De igual manera, algunos trabajos evidencian los buenos resultados de otros métodos como los sistemas basados en la bioimpedancia para monitorizar el deterioro del cartílago articular. Sin embargo, los dispositivos de tomografía por impedancia eléctrica aún no han sido estudiados ampliamente en la evaluación de lesiones articulares.

Conclusión: Se han desarrollado prototipos electrónicos de tomografía por impedancia eléctrica de bajo costo que han permitido detectar y reconocer gestos realizados con la mano a partir del análisis de la distribución de la conductividad en la articulación de la muñeca, lo que nos permite inferir que la tomografía por impedancia eléctrica podría ser una buena alternativa para la monitorización de lesiones articulares.

Originalidad: En la literatura no se evidencian estudios enfocados al desarrollo e implementación de sistemas de tomografía por impedancia eléctrica en aplicaciones médicas relacionadas con las lesiones articulares.

Limitaciones: En este artículo de revisión únicamente se mencionan aquellos estudios que describen los métodos de biomágenes no invasivos utilizados para evaluar enfermedades articulares, incluyendo las aplicaciones médicas de los sistemas de tomografía por impedancia eléctrica.

Palabras clave: Enfermedades articulares, Monitoreo articular, Bioimagen, Bioimpedancia, Tomografía por impedancia eléctrica (TIE).

Resumo

Introdução: O artigo de revisão mostra o estado da arte das diferentes técnicas de monitoramento de lesões articulares, este trabalho é o produto do projeto de pesquisa "Viabilidade da tomografia por impedância elétrica para monitoramento de lesões articulares", que ocorre na Universidade de Cauca durante o período 2018-2019.

Objetivo: Identificar os métodos de imagens biológicas não invasivas utilizadas na avaliação de doenças articulares.

Metodologia: Seleção e revisão de artigos relacionados à avaliação de lesões articulares utilizando tecnologias não invasivas de bio-imagem por meio de mapeamento sistemático.

Resultados: Os sistemas de ressonância magnética e tomografia computadorizada constituem os métodos não invasivos de maior confiabilidade e aplicação na avaliação de lesões articulares. Da mesma forma, alguns estudos mostram os bons resultados de outros métodos, como sistemas baseados em bioimpedância, para monitorar a deterioração da cartilagem articular. No entanto, os dispositivos de tomografia por impedância elétrica ainda não foram amplamente estudados na avaliação de lesões articulares.

Conclusão: Foram desenvolvidos protótipos eletrônicos da tomografia de impedância elétrica de baixo custo que permitiram detectar e reconhecer gestos com as mãos a partir da análise da distribuição da condutividade na articulação do punho, o que nos permite inferir que a A tomografia por impedância elétrica pode ser uma boa alternativa para o monitoramento de lesões articulares.

Originalidade: Não há evidências na literatura focadas no desenvolvimento e implementação de sistemas de tomografia por impedância elétrica em aplicações médicas relacionadas a lesões articulares.

Limitações: Este artigo de revisão menciona apenas os estudos que descrevem os métodos não invasivos de bioimagem usados para avaliar doenças articulares, incluindo as aplicações médicas de sistemas de tomografia por impedância elétrica.

Palavras-chave: Doenças articulares, Monitoramento articular, Bioimagem, Bioimpedância, Tomografia por impedância elétrica (SIT).

1. INTRODUCTION

Chronic rheumatic diseases have generated an increase in morbidity and disability rates in a large part of the population, due to the damage they cause in connective organs and tissues such as cartilage, synovium and skin [1], [2]. Among these diseases is arthritis, known to be the cause of inflammation and joint pain and from which disorders such as rheumatoid arthritis, juvenile idiopathic, osteoarthritis, gout, among others are derived. These prevent the normal development of daily activities that people exercise, by generating deterioration in the articular cartilage, muscles

and ligaments, as a result of making greater efforts or as the product of elderly age in people, thus reducing the quality of life [3]-[5].

Rheumatoid arthritis is characterized by chronic synovial inflammation leading to bone erosion and joint destruction [6], while juvenile idiopathic arthritis, on the other hand, is an inflammatory disease that affects young people and for which the causes that generate it remain unknown, but could be related to the combination of both genetic and environmental factors [7]. Osteoarthritis is known in the medical field as the cause of the deterioration of articular cartilage producing swelling, pain and loss of movement as a result of friction between the bones due to changes at the tissue, molecular and cellular level [8], [9]. Finally, gout is a disorder responsible for affecting the joints by the accumulation of uric acid crystals affecting several joints and is also a degenerative disease [10], [11].

Technological developments have allowed for the construction and implementation of systems such as magnetic resonance, computed tomography, ultrasound, among others, which are used in medical applications related to the diagnosis and detection of diseases that compromise the joints; however, recent studies have been carried out that propose the use of systems based on bio-impedance to evaluate the deterioration of articular cartilage [12]-[16].

This paper is focused on the systematic literature review related to bio-image systems development, oriented to the study of the non-invasive methods for the evaluation of joint diseases.

2. MATERIALS Y METHODS

The systematic review is based on [79], which consists of three phases, which obtain publications that evidenced the trend of research with respect to the study and development of non-invasive bio-image technologies for the evaluation of joint injuries.

2.1 Phase 1. Search chains.

Search chains were developed related to diagnosis, therapy and technologies used in the evaluation of joint injuries, which found works in scientific databases such as IEEE, Xplore Digital Library and ScienceDirect. 4280 papers have been found in this phase, related to non-invasive techniques in the monitoring, detection and therapy of joint diseases.

2.2 Phase 2. Exclusion criteria.

For the selection of the most relevant papers for the topic of this work, some exclusion criteria were applied: i) works published in the last four years (2014-2018), ii) papers in English or Spanish and iii) different from theses and technical reports. As a result, 156 papers were selected.

2.3 Phase 3. Data extraction.

Finally, the data extraction was carried out taking into account for the title and summary of the publications, obtaining in this way 79 papers related to the study of joint diseases and non-invasive techniques used in the diagnosis, evaluation and treatment of these conditions.

3. RESULTS

Figure 1 shows the trend of the application of non-invasive bio-image methods in the diagnosis, detection and treatment of joint injuries.

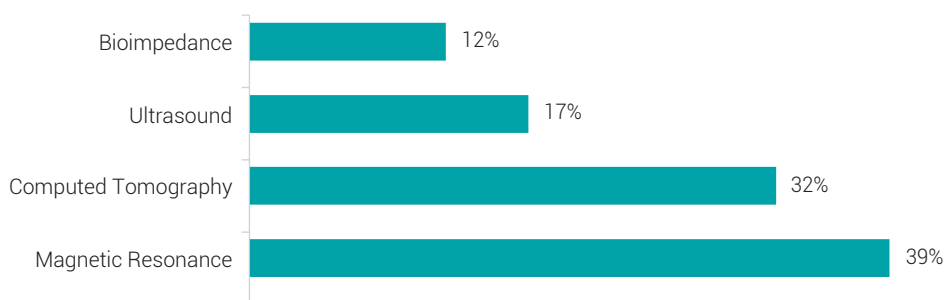


Figure 1. Non-invasive diagnostic methods of joint diseases.

Source: the authors

Based on the literature review, the results obtained clearly show magnetic resonance (MR) and computed tomography (CT) are the non-invasive technologies of greater medical application because of their capacity to diagnose and detect diseases that compromise the joints, compared to techniques frequently used such as x-rays. [17] highlights the efficiency of both CT and magnetic resonance imaging (MRI) in the diagnosis of astragalus lesions, allowing for preoperative fundamental planning in surgical decision-making, as well as the classification of this type of disease. Ultrasound helps determine the typical morphology of these conditions, unlike x-rays that are not efficient in the early evaluation of the disease when it comes to minimal damage.

On the other hand, [9] emphasizes the importance of the MRI in the evaluation of osteoarthritis and its progression, due to the limitations that radiography presents before the diagnosis and monitoring in the early stages and during the progression of the disease. Finally, [18] obtains good results when using MRI and CT compared to radiography, in the detection of acute inflammation during bone erosion in people suffering from spondylarthritis [18].

3.1 Magnetic resonance imaging (MRI)

MRI devices provide bio-images of human tissues when subjected to a magnetic field [19]. Based on this fact, MRI has been a reliable technique in medical applications, particularly to diagnose joint diseases, since it allows for the monitoring of progressive joint cartilage deterioration as a consequence of osteoarthritis [9], [20]. Additionally, it is useful both in the early evaluation of this disease and in the detection of defects that compromise the astragalus [21].

The detection of cartilage lesions in early stages is usually based on the evaluation of morphological changes and alterations in the biochemical properties of articular cartilage [22], [23]. These changes, generated by tears in the acetabular labrum, have been accurately diagnosed using indirect MR arthrography as seen in [22]. However, this study has some related limitations; first with the reference standard, in this case the arthroscopy, since it has drawbacks in the complete visualization of the surfaces that are in the articulation, and second, to not include patients with healthy acetabular labrum in the taking of images [22]. On the other hand, the MRI of enhanced cartilage with standardized late gadolinium could considerably optimize the preoperative evaluation of articular cartilage for the surgeon's decision-making on patients with acetabular shock, despite some limitations due to the fact that it is a retrospective study with a small group of patients [24]. In some cases, disorders in the articular cartilage can develop as a consequence of meniscal tears without radiographic osteoarthritis, which have been determined through RM providing information that could link the meniscal injury with osteoarthritis to have a high sensitivity and specificity [20], [25]; in addition, [26] uses RM without contrast to detect glenohumeral articular cartilage lesions in patients with rotator cuff tendinopathy. Although the results obtained according to this study lacked a standardized protocol because shoulder MR analyzes were performed in different institutions leading to high variability, this method has good diagnostic accuracy, allowing future work to focus on MR sequences to identify and characterize articular cartilage lesions [26].

On the other hand, ankle injuries are another type of condition in which MRI systems have been used to analyze the long-term effects of the removal of joint load on the quality of knee cartilage in patients diagnosed with ankle injury. Early changes in the cartilage were detected, however, the actual load was not monitored continuously, therefore it is unknown if the patients were unloading the affected leg [27]. Another use of MRI determines the prevalence of the distal tibioperoneal syndesmosis lesion, due to chronic instability of the ankle [28]. This method is very useful for the detection of all types of ankle ligament injury and is essential in the preoperative interpretation. However, the study was limited by the small number of patients and that interobserver and intraobserver reliability was not evaluated [28].

Knee injuries are one of medical conditions for which MRI shows a good capacity for diagnostic accuracy [29]. A study in which the use of low intensity MRI is recommended is in the detection of substantial abnormalities in menisci of the knee; however, this technique is not applied in this study for the diagnosis and classification of cartilage defects and knee osteoarthritis due to insufficient evidence [29]. With respect to the medial meniscus, MRI does not represent a promising technique in the evaluation of the chondral defect, especially when it comes to partial thickness defects, although its diagnostic accuracy is important in the detection of full-thickness chondral defects [30]. In addition, it should be mentioned that in [30] there are some limitations since the data related to the orthopedic evaluation of the knee are insufficient and the study population is relatively low although this method has made it possible to describe the level of syndesmotic ligament injury based on an intraoperative evaluation [31].

3.2 Computed tomography

Computed tomography (CT) is one of the methods of great diagnostic potential in joint-related diseases due to its sensitivity when detecting acute traumatic knee injuries [32]-[33], its ability to detect articular cartilage lesions and subchondral bone alterations simultaneously from quantitative images of the knee [33], its evaluation and accurate detection of tears and rupture of the anterior cruciate ligament [34] and in wrist joints to evaluate the distal radioulnar joint in post-traumatic wrists for the inter-observer and intra-observer [35]. This is based on the application of x-rays on the affected area obtaining information that is then processed by a computer using algorithms to generate medical images [36].

In general, joint diseases are mostly associated with the deterioration of articular cartilage; the enhanced contrast CT being very useful, since it can provide important information about articular cartilage affections caused by enzymes and

damages caused by mechanical impacts. According to [39], it can even lead to a better selection of surgical treatment options specific to a patient, preventing post-traumatic osteoarthritis. However, this study presents some limitations related to the measurement of cartilage thickness from histology [37]. Likewise, cone beam CT is very good at detecting osteoarthritic changes in the mandibular condyle [38].

On the other hand, studies show different applications related to joints in which CT has been used successfully, such as in [39] in which the use of CT arthrography with a radial plane view to diagnose and classify foveal lesions due to a high specificity, provided better results than MRI. It should be noted that the study has some drawbacks such as a small sample size, lack of contrast of soft tissues, patient exposure to radiation and its discomfort due to contrast injection [39]. [40] highlights the good results obtained from CT arthrography when detecting defects in the cruciate ligaments, proximal tibial and ligament enthesis when compared to radiographs, ultrasonography and arthroscopy; however, the study did not consider a reference for the structures of the femorotibial joint, which calls into question the reliability of the detection of definitive lesions [40]. [41] emphasizes the use of multidetector CT to evaluate anomalies in the tendons. In [42], the good results in the application of CT in animals and humans stand out to characterize the non-destructive distribution of collagen in the total volume of the articular cartilage, giving rise to the development of new non-destructive histopathological mechanisms. This method has some limitations, such as the small size of the sample and the accuracy reduction of the results due to the CT device, especially when using the animal model [42]. Finally, four-dimensional CT allows for the detection of subluxation by capitation early, which would lead to timely treatment of the disease, avoiding the patient's growing morbidity [43].

3.3 Ultrasound

Bio-images can be generated with ultrasound devices, part of the emission of high frequency sound waves [44], and be used in different medical applications for the identification of extensor tendon lacerations with reliable and precise results. The limitations stem from this method being tested on cadavers, which implies the lack of typical edema and hemorrhage associated with the extremities with acute trauma [45]. This method determines quantitative and semiquantitative measures of synovial hypertrophy in joints of different dimensions on asymptomatic volunteers, obtaining the highest measurements in the first and second metatarsophalangeal joint of small size, talonavicular recess of medium size and large hip [46]. Another important application is the local supply of medical agents in *in-vitro* bovine cartilage by means of

intense ultrasound [47]. This would allow the development of new therapeutic strategies with medicines for osteoarthritis, although it must be taken into account that the properties of *in-vitro* bovine cartilage can differ significantly from human cartilage *in-vivo* [47]. Likewise, based on good correlation of results obtained between ultrasound and MRI, it has been possible to evaluate synovial inflammation determining the severity level of patients with arthritis rheumatoid, although the experiment was tested on patients with rheumatoid arthritis with a relatively short duration of the disease [48].

3.4 Bioimpedance

Methods based on electrical signals are technologies that have been of great support in the study of articular cartilage deterioration [12]-[16]. [15] mentions the use of electroarthrography as a promising technique for the non-invasive diagnosis of articular cartilage deterioration and arthritis, with good results. This work used an 8 electrode distribution measuring the potentials generated by articular cartilage with a sampling frequency of 800 Hz. On the other hand, in [16] 3D knee models were constructed taking into account electrical properties of the unbent healthy right knee. Potentials are produced by the articular cartilage and the meniscus for this location with the eight electrodes on the lateral and medial part of the knee. This work highlights the importance of computer modeling since it is possible to qualitatively improve the understanding of the generation of the electroarthrography signal, demonstrating the ability of this method to detect and locate articular cartilage lesions [16].

Similarly, [12] formed two groups of patients. The control group consisted of people with healthy knees and the second group, the osteoarthritis group, consisted of patients with pathological knees. The electrodes were located in the upper and lower part of the patella applying signals with a frequency of 1 kHz [12]; the experiment showed a difference between the impedance distribution between the groups. This work focused on the impedance distribution with the legs extended and flexed without load and walking in a controlled environment [12], [13]. [13] took into account volunteers with healthy and pathological knees, using tetrapolar electrodes introducing currents of 2mA at 20 kHz; the results obtained were important, so they concluded that plethysmography, as a non-invasive method, could be used to diagnose osteoarthritis of the knee [12], [13]. This technique quantitatively measured the mechanical properties of articular cartilage in an animal model treated with enzymes determining the correlation between mechanical and electrical properties [14].

Electrical impedance tomography (EIT) systems are characterized by their ability to estimate the internal structural conductivity distribution of any object by means of the application of alternating currents with frequencies usually higher than 50 kHz, measuring the potentials generated by means of electrodes located on the object boundary and after that, using image reconstruction algorithms, it is possible to estimate the impedance distribution of the studied object [49], [50]. This non-invasive method has not yet penetrated into medical applications related to joint injuries, although it has been used in the detection and recognition of hand gestures based on the distribution of conductivity in the wrist joint, showing promising results [49], [51]-[53].

[49] used eight electrodes located on the arm. The signal had a predetermined frequency of 200 kHz, measuring a minimum impedance of 6.4 ohms and classifying up to 19 hand gestures with an accuracy of 98% [49], whereas [51] employed 32 electrodes applying a 40 kHz signal, obtaining better results with a configuration of four-pole electrodes in comparison with that of two-poles allowing for higher resolution. Finally, [53] made use of 8 electrodes located on the arm and on the wrist through which they applied a 40 kHz signal that distinguished between different hand gestures during the experiment. In the case of the measurements performed on the arm, the average accuracy was 93.1 % while the measurements on the wrist reached an average 96.6 % accuracy [53].

It should be noted that bio-impedance represents a good option to evaluate, diagnose and monitor joint injuries, taking into account that they are based on electrical signals and therefore do not generate radiation unlike CT [9], which can affect some organs like the heart and lungs [55]. In addition it does not need any type of substance to improve the contrast that could have negative effects on the health of the patient compared for example with MRI [24]. Some disadvantages presented by ultrasound have to do with the dependence of diagnostic support techniques due to high inter-operator variability [78]. On the other hand, its effectiveness is reduced when evaluating osteoarthritis progression [9].

Table 1 shows the different works of bioimpedance related with joints and the characteristics of the devices used, demonstrating the viability of these techniques in the study of joint diseases. The low cost of the development of bioimpedance measurement equipment, is another advantage of this technique.

Table 1. Bioimpedance and joints.

Application	Number of Electrodes	Applied signal frequency
Novel method of using Dynamic electrical impedance signals for noninvasive diagnosis of knee osteoarthritis [12]	2	1 kHz
Electrical impedance signals for noninvasive diagnosis of knee osteoarthritis [13]	2	20 kHz
Evaluation of mechanical properties of articular cartilage [14]	2	10 kHz
Towards a high accuracy wearable hand gesture recognition system [49]	8	200 kHz
Advanced recognition of hand gestures [51]	8	40 kHz
Electrical impedance tomography for hand gesture recognition [53]	8	40 kHz

Source: the authors

4. DISCUSSION

Despite the fact that MRI, CT and ultrasound systems are non-invasive methods frequently used in medical applications corresponding to the detection, diagnosis and monitoring of joint diseases, they all have certain limitations that affect its use in some way. MRI is not usually used at the onset of osteoarthritis of the knee due to its high cost [54], leading to limited availability of this technology [77]. It is also not very accurate when trying to detect slight damage in articular cartilage [26]. On the other hand, the most relevant limitation of the CT as a means of diagnosis, is related to the radiation dose that it generates since its principle of operation is based on the application of x-rays [9], taking into account that organs such as the lungs, heart, among others, are highly sensitive to radiation [55]. On the other hand, their sensitivity is affected when trying to detect slight changes in the joints produced by osteoarthritis [38], and ultrasound it is less effective in evaluating the progression of diseases such as osteoarthritis [9].

It should be highlighted that EIT, is a non-invasive technique that does not generate radiation [56], [57], providing greater patient safety, although not yet widely studied as a possible method for monitoring joint injuries. This technique allows for the evaluation, diagnosis and detection of diseases such as: pneumothorax [58], brain disorders [59], [60], lung diseases in which both the effects of positive end-expiratory pressure are determined [61], [62], flow of gas in regions of the lungs [63], [64] and regional changes in the ventilation distribution [65], [66], among others. Also, EIT systems have been developed that made it possible to detect and recognize hand gestures,

based on the distribution of conductivity; making this technique a viable alternative in the study of joints [49], [51].

On the other hand, it is important to bear in mind that medical devices have an important role in the evaluation of different rheumatic diseases, making possible the diagnosis, measurement, monitoring and timely treatment of the injury or disease and thus improving the quality of life of people [67]. With respect to the evaluation of joint diseases by means of MRI, devices such as the 3-T systems (Achieva 3.0T TX, Philips Healthcare) [20] and MR 3.0-T (VERIO, Siemens) [22] are used. Some CT devices used in the diagnosis of these pathologies are the peripheral CBT scanner [33] and dual-source CT (Siemens Healthcare) [34]. Likewise, the evaluation of joint injuries has been carried out by means of ultrasound devices such as the Logiq E9 General Electric US [45], MyLab 60 Xvision [46] and the Toshiba AplioXG scanner [48], showing the wide acceptance of medical images in the medical field.

As to EIT, there are commercial equipment such as the Pulmovista 500 [61], [64] and GOE MF II [68], [69], which have been developed and implemented for the diagnosis of different types of injuries with most related to pulmonary disorders, however, different electronic prototypes have been proposed using DSPs (Digital Signal Processor) [70], FPGAs (Field Programmable Gate Array) [71] and microcontrollers [72], [73]. These obtain tomographic images by taking into account the arrangement and geometry of the surface electrodes, the variation of the parameters of application and measurement of the signals and the image reconstruction algorithms [70], [71], [73]. This technique a promising option in joint monitoring as well as using low cost devices when compared to MRI and CT equipment. It is worth mentioning that the image reconstruction algorithms are part of an important field of research interest related to EIT, with EIDORS being the tool on which most of the works focused on this area of research have been based [74]-[76].

5. CONCLUSIONS

The results obtained in the literature review clearly show that MRI and CT systems are an important part of the non-invasive methods of greater reliability in the diagnosis of joint injuries. However, it is to be taken into account that despite the wide transcendence of these techniques in the monitoring of joints, there are certain limitations that affect their use, either by access and cost effects (in the beginning of the disease) or the radioactive energy generation, that could affect sensitive organs. Due to this fact, it is important to take into account the development of new devices such as EIT, which are free of radioactive energies, which have not yet penetrated into medical

applications such as the evaluation of joint injuries, but which have obtained promising results with respect to the detection and recognition of hand gestures, being a good alternative for the detection and monitoring of joint behavior.

Likewise, the development of EIT systems based on devices such as DSPs, FPGAs and microcontrollers, represent an opportunity to improve the accessibility to technologies in the field of physiatry, due to its robustness and its low cost compared to the systems that are currently commercially available.

Finally, the study of EIT includes three important aspects to consider and on which the performance of this non-invasive method depends, such as: i) the geometric arrangement of the surface electrodes, ii) the variation of the parameters of application and measurement of signals; and iii) algorithms for the reconstruction of tomographic images; aspects that require a broad study to improve the reliability in the joint diseases field.

6. REFERENCIAS

- [1] M. Maini, F. Adelowo, J. Saleh, Y. Weshahi, G. R. Burmester, M. Cutolo, J. Flood, L. March, H. M. D. Blumer, K. Pile, C. Pineda, C. Thorne, and T. K. Kvien, "The global challenges and opportunities in the practice of rheumatology: White paper by the world forum on rheumatic and musculoskeletal diseases," *Clinical Rheumatology*, vol. 34, no. 5, pp. 819-829, May 2015. [Online]. doi: <https://doi.org/10.1007/s10067-014-2841-6>.
- [2] W. Marder, É. Vinet, and E. C. Somers, "Rheumatic autoimmune diseases in women and mid-life health," *Women's Midlife Health*, vol. 1, no. 11, pp. 1-8, Dec 2015. [Online]. doi: <https://doi.org/10.1186/s40695-015-0012-9>.
- [3] G. Musumeci, "The effect of mechanical loading on articular cartilage," *Journal of Functional Morphology and Kinesiology*, vol. 1, no. 2, pp. 154-161, 2016. [Online]. doi: <https://doi.org/10.3390/jfmk1020154>.
- [4] E. M. Gravallesse, S. R. Goldring, and G. Schett, "Chapter 13 - the role of the immune system in the local and systemic bone loss of inflammatory arthritis," *Osteoimmunology: Interactions of the Immune and Skeletal Systems*, pp. 241-256, 2016. [Online]. doi: <https://doi.org/10.1016/B978-0-12-800571-2.00013-X>.
- [5] R. Cimaz, "Systemic-onset juvenile idiopathic arthritis," *Autoimmunity Reviews*, pp. 1-4, 2016. [Online]. doi: <https://doi.org/10.1016/j.autrev.2016.07.004>.

- [6] G. S. Firestein and I. B. McInnes, "Immunopathogenesis of rheumatoid arthritis," *Immunity*, vol. 46, no. 2, pp. 183-196, 2017. [Online]. doi: <https://doi.org/10.1016/j.immuni.2017.02.006>.
- [7] A. O. Hersh and S. Prahalad, "Immunogenetics of juvenile idiopathic arthritis: A comprehensive review," *Journal of Autoimmunity*, vol. 64, pp. 113-124, 2015. [Online]. doi: <https://doi.org/10.1016/j.jaut.2015.08.002>.
- [8] I. Afara, I. Prasadam, Z. Arabshahi, Y. Xiao, and A. Oloyede, "Monitoring osteoarthritis progression using near infrared (nir) spectroscopy," *Scientific Reports*, vol. 7, no. 11463, pp. 1-9, 2017. [Online]. doi: <https://doi.org/10.1038/s41598-017-11844-3>.
- [9] Q. Li, K. Amano, T. Link, and C. Ma, "Advanced imaging in osteoarthritis," *Sports Health*, vol. 8, no. 5, pp. 418-428, 2016. [Online]. doi: <https://doi.org/10.1177/1941738116663922>.
- [10] J. A. Singh, "Gout: will the "king of diseases" be the first rheumatic disease to be cured?," *BMC Medicine*, vol. 14, no. 180, pp. 1-5, 2016. [Online]. doi: <https://doi.org/10.1186/s12916-016-0732-1>.
- [11] F. P. Ruiz, N. Dalbeth, and T. Bardin, "A review of uric acid, crystal deposition disease, and gout," *Advances in Therapy*, vol. 32, no. 1, pp. 31-41, 2015. [Online]. doi: <https://doi.org/10.1007/s12325-014-0175-z>.
- [12] S. S. Gajre, S. Anand, U. Singh, and R. K. Saxena, "Novel method of using Dynamic electrical impedance signals for noninvasive diagnosis of knee osteoarthritis," *International Conference of the IEEE Engineering in Medicine and Biology Society. IEEE*, pp. 2207-2210, 2006. [Online]. doi: <https://doi.org/10.1109/IEMBS.2006.260671>.
- [13] S. S. Gajre, U. Singh, R. K. Saxena, and S. Anand, "Electrical impedance signal analysis in assessing the possibility of non-invasive diagnosis of knee osteoarthritis," *Journal of medical engineering & technology*, vol. 31, no. 4, pp. 288-299, 2007. [Online]. doi: <https://doi.org/10.1080/03091900600863745>.
- [14] Y. Morita, S. Suzuki, H. Kondo, and N. Tomita, "A feasibility study for evaluation of mechanical properties of articular cartilage with a two-electrode electrical impedance method," *Journal of Orthopaedic Science*, vol. 17, no. 3, pp. 272-280, 2012. [Online]. doi: <https://doi.org/10.1007/s00776-012-0208-x>.
- [15] A.M. Préville, P. Lavigne, M. Buschmann, J. Hardin, Q. Han, L. Djerroud, and P. Savard, "Electroarthrography: a novel method to assess articular cartilage and diagnose osteoarthritis by non-invasive measurement of load-induced electrical potentials at the surface of the

- knee,” *Osteoarthritis and cartilage*, vol. 21, no. 11, pp. 1731-1737, 2013. [Online]. doi: <https://doi.org/10.1016/j.joca.2013.07.003>.
- [16] Q. Han, M.D. Buschmann and P. Savard “The forward problem of electroarthrography: Modeling load-induced electrical potentials at the surface of the knee,” *IEEE Transactions On Biomedical Engineering*, vol. 61, no. 7, pp. 2020-2027, 2014. [Online]. doi: <https://doi.org/10.1109/TBME.2014.2312104>.
- [17] R. M. Gerards, K. T. M. Opdam, C. J. A. van Bergen, C. N. van Dijk, “Diagnostic imaging modalities for osteochondral defects of the talus,” *Fuß & Sprunggelenk*, vol. 13, no. 2, pp. 78 – 84, 2015. [Online]. doi: <https://doi.org/10.1016/j.fuspru.2015.04.003>.
- [18] L. Hu, Z. Huang, X. Zhang, Q. Chan, Y. Xu, G. Wang and W. Wang, “The performance of MRI in detecting subarticular bone erosion of sacroiliac joint in patients with spondyloarthropathy: A comparison with X-ray and CT,” *European Journal of Radiology*, vol. 83, no. 11, pp. 2058 – 2064, 2014. [Online]. doi: <https://doi.org/10.1016/j.ejrad.2014.08.009>.
- [19] P.B. Grover, M. Tognarelli, M.E. Crossey, I. J. Cox, D. T. Robinson and J.W. McPhail. “Magnetic Resonance Imaging: Principles and Techniques: Lessons for Clinicians,” *Journal of Clinical and Experimental Hepatology*, Vol. 5, No. 3, pp. 246 - 255, 2015. [Online]. doi: <https://doi.org/10.1016/j.jceh.2015.08.001>.
- [20] H. Matsubara, K. Okazaki, Y. Takayama, K. Osaki, Y. Matsuo, H. Honda, Y. Iwamoto, “Detection of early cartilage deterioration associated with meniscal tear using t1p mapping magnetic resonance imaging,” *BMC Musculoskeletal Disorders*, vol. 16, no. 22, 2015. [Online]. doi: <https://doi.org/10.1186/s12891-015-0487-4>.
- [21] J. Le, Q. Peng, and K. Sperling, “Biochemical magnetic resonance imaging of knee articular cartilage: T1rho and t2 mapping as cartilage degeneration biomarkers,” *Annals of the New York Academy of Sciences*, vol. 1383, no. 1, pp. 34-42, 2016. [Online]. doi: <https://doi.org/10.1111/nyas.13189>.
- [22] C.N. Petchprapa, L.D. Rybak, K.S. Dunham, R. Lattanzi and M.P. Recht, “Labral and cartilage abnormalities in young patients with hip pain: accuracy of 3-Tesla indirect MR arthrography,” *Skeletal Radiology*, vol. 44, no. 1, pp. 97-105, 2015. [Online]. doi: <https://doi.org/10.1007/s00256-014-2013-4>.
- [23] S.C. Peers, T. Maerz, E.A. Baker, A. Shetty, Y. Xia, S. Puwal, D. Marcantonio and D. Guettler, “T1p magnetic resonance imaging for detection of early cartilage changes in knees of asymptomatic collegiate female impact and nonimpact athletes,” *Clinical Journal of Sport Medicine*, vol. 24, no. 3, pp. 218-225, 2014. [Online]. doi: <https://doi.org/10.1097/JSM.000000000000013>.

- [24] R. Lattanzi, C. Petchprapa, D. Ascani, J.S. Babb, D. Chu, R.I. Davidovitch, T. Youm, R.J. Meislin and M.P. Recht, "Detection of cartilage damage in femoroacetabular impingement with standardized dGEMRIC at 3T," *Osteoarthritis and Cartilage*, vol. 22, no. 3, pp. 447-456, 2014. [Online]. doi: <https://doi.org/10.1016/j.joca.2013.12.022>.
- [25] C. Gatlin, L. Matheny, C. Ho, N. Johnson, and T. Clanton, "Diagnostic accuracy of 3.0 tesla magnetic resonance imaging for the detection of articular cartilage lesions of the talus," *Foot and Ankle International*, vol. 36, no. 3, pp. 288-292, 2014. [Online]. doi: <https://doi.org/10.1177/1071100714553469>.
- [26] C. VanBeek, B. Loeffler, A. Narzikul, V. Gordon, M. Rasiej, J. Kazam, and J. Abboud, "Diagnostic accuracy of noncontrast mri for detection of glenohumeral cartilage lesions: A prospective comparison to arthroscopy," *Journal of Shoulder and Elbow Surgery*, vol. 23, no. 7, pp. 1010-1016, 2014. [Online]. doi: <https://doi.org/10.1016/j.jse.2014.01.048>.
- [27] H. Owman, C.J. Tiderius, Y.B. Ericsson and L.E. Dahlberg, "Long-term effect of removal of knee joint loading on cartilage quality evaluated by delayed gadolinium-enhanced magnetic resonance imaging of cartilage," *Osteoarthritis and Cartilage*, vol. 22, no. 7, pp. 928-932, 2014. [Online]. doi: <https://doi.org/10.1016/j.joca.2014.04.021>.
- [28] K. Y. Chun, Y. S. Choi, S. H. Lee, J. S. Kim, K. W. Young, M. S. Jeong and D. J. Kim, "Deltoid ligament and tibiofibular syndesmosis injury in chronic lateral ankle instability: Magnetic resonance imaging evaluation at 3t and comparison with arthroscopy," *Korean Journal of Radiology*, vol. 16, no. 5, pp. 1096-1103, 2015. [Online]. doi: <https://doi.org/10.3348/kjr.2015.16.5.1096>.
- [29] S. Puig, Y. Kuruvilla, L. Ebner, and G. Endel, "Magnetic resonance tomography of the knee joint," *Skeletal Radiology*, vol. 44, no. 10, pp. 1427-1434, 2015. [Online]. doi: <https://doi.org/10.1007/s00256-015-2178-5>.
- [30] L. Felli, G. Garlaschi, A. Muda, A. Tagliafico, M. Formica, A. Zanirato and M. Mazzola, "Comparison of clinical, MRI and arthroscopic assessments of chronic ACL injuries, meniscal tears and cartilage defects," *Musculoskeletal Surgery*, vol. 100, no. 3, pp. 231-238, 2016. [Online]. doi: <https://doi.org/10.1007/s12306-016-0427-y>.
- [31] S. J. Warner, M. R. Garner, P. C. Schottel, R. M. Hinds, M. L. Loftus and D. G. Lorich, "Analysis of PITFL injuries in rotationally unstable ankle fractures," *Foot and Ankle International*, vol. 36, no. 4, pp. 377-382, 2015. [Online]. doi: <https://doi.org/10.1177/1071100714558845>.
- [32] J. X. Cao, Y. M. Wang, X. Q. Kong, C. Yang, and P. Wang, "Good interrater reliability of a new grading system in detecting traumatic bone marrow lesions in the knee by dual energy ct

- virtual non-calcium images,” *European Journal of Radiology*, vol. 84, no. 6, pp. 1109-1115, 2015. [Online]. doi: <https://doi.org/10.1016/j.ejrad.2015.03.003>.
- [33] K. Myller, M. Turunen, J. Honkanen, S. Vaananen, J. Iivarinen, J. Salo, J. Jurvelin, and J. Toyras, “In vivo contrast-enhanced cone beam ct provides quantitative information on articular cartilage and subchondral bone,” *Annals of Biomedical Engineering*, vol. 45, no. 3, pp. 811-818, 2017. [Online]. doi: <https://doi.org/10.1007/s10439-016-1730-3>.
- [34] K. N. Glazebrook, L. J. Brewerton, S. Leng, R. E. Carter, P. C. Rhee, N. S. Murthy, B. M. Howe, M. D. Ringle, D. L. Dahm, M. J. Stuart, C. H. McCollough and J. G. Fletcher, “Case-control study to estimate the performance of dual-energy computed tomography for anterior cruciate ligament tears in patients with history of knee trauma,” *Skeletal Radiology*, vol. 43, no. 3, pp. 297-305, 2014. [Online]. doi: <https://doi.org/10.1007/s00256-013-1784-3>.
- [35] M. Wijffels, W. Stomp, P. Krijnen, M. Reijnierse and I. Schipper, “Computed tomography for the detection of distal radioulnar joint instability: normal variation and reliability of four CT scoring systems in 46 patients,” *Skeletal Radiology*, vol. 45, no. 11, pp. 1487-1493, 2016. [Online]. doi: <https://doi.org/10.1007/s00256-016-2455-y>.
- [36] S. Mirsadraee and E. J. R. van Beek. “Functional Imaging: Computed Tomography and MRI,” *Clinics in Chest Medicine*, Vol. 36, No. 2, pp. 349 - 363, 2015. [Online]. doi: <https://doi.org/10.1016/j.ccm.2015.02.014>.
- [37] A. Saukko, J. Honkanen, W. Xu, S. Vaananen, J. Jurvelin, V. P. Lehto, and J. Toyras, “Dual contrast ct method enables diagnostics of cartilageinjuries and degeneration using a single ct image,” *Annals of Biomedical Engineering*, vol. 45, no. 12, pp. 2857-2866, 2017. [Online]. doi: <https://doi.org/10.1007/s10439-017-1916-3>.
- [38] S. Yadav, L. Palo, M. Mahdian, M. Upadhyay, and A. Tadinada, “Diagnostic accuracy of 2 cone-beam computed tomography protocols for detecting arthritic changes in temporomandibular joints,” *American Journal of Orthodontics and Dentofacial Orthopedics*, vol. 147, no. 3, pp. 339 - 344, 2015. [Online]. doi: <https://doi.org/10.1016/j.ajodo.2014.11.017>.
- [39] H. Moritomo, S. Arimitsu, N. Kubo, T. Masatomi and M. Yukioka, “Computed tomography arthrography using a radial plane view for the detection of triangular fibrocartilage complex foveal tears,” *Journal of Hand Surgery*, vol. 40, no. 2, pp. 245-251, 2015. [Online]. doi: <https://doi.org/10.1016/j.jhssa.2014.10.051>.
- [40] B. Nelson, C. Kawcak, L. Goodrich, N. Werpy, A. ValdAc s-MartAnez, and C. Mcllwraith, “Comparison between computed tomographic arthrography, radiography, ultrasonography and

arthroscopy for the diagnosis of femorotibial joint disease in western performance horses,” *Veterinary radiology & ultrasound*, vol. 57, no. 4, pp. 387-402, 2016. [Online]. doi: <https://doi.org/10.1111/vru.12366>.

- [41] S. Demehri, M. Chalian, S.J. Farahani, E.K. Fishman and L.M. Fayad, “Detection and characterization of tendon abnormalities with multidetector computed tomography,” *Journal of Computer Assisted Tomography*, vol. 38, no. 2, pp. 299-307, 2014. [Online]. doi: <https://doi.org/10.1097/RCT.0b013e3182aa72bf>.
- [42] H. J. Nieminen, T. Ylitalo, S. Karhula, J. P. Suuronen, S. Kauppinen, R. Serimaa, E. Hæggström, K. P. H. Pritzker, M. Valkealahti, P. Lehenkari, M. Finnilä, S. Saarakkala, “Determining collagen distribution in articular cartilage using contrast-enhanced micro-computed tomography,” *Osteoarthritis and Cartilage*, vol. 23, no. 9, pp. 1613 – 1621, 2015. [Online]. doi: <https://doi.org/10.1016/j.joca.2015.05.004>.
- [43] S. E. Repse, B. Amis and J. M. Troupis, “Four-dimensional computed tomography and detection of dynamic capitate subluxation,” *Journal of Medical Imaging and Radiation Oncology*, vol. 59, no. 3, pp. 331-335, 2015. [Online]. doi: <https://doi.org/10.1111/1754-9485.12260>.
- [44] A. E. J. Powles, D. J. Martin, I. T. P. Wells and C. R. Goodwin. “Physics of ultrasound,” *Anaesthesia & Intensive Care Medicine*, vol. 19, no. 4, pp. 202 - 205, Apr. 2018. [Online]. doi: <https://doi.org/10.1016/j.mpaic.2018.01.005>.
- [45] B. Dezfuli, M. S. Taljanovic, D. M. Melville, E. A. Krupinski and J. E. Sheppard, “Accuracy of High-Resolution Ultrasonography in the Detection of Extensor Tendon Lacerations,” *Annals of Plastic Surgery*, vol. 76, no. 2, pp. 187-192, 2016. [Online]. doi: <https://doi.org/10.1097/SAP.0000000000000524>.
- [46] F. Machado, J. Natour, R. Takahashi, and R. Furtado, “Articular ultrasound in asymptomatic volunteers: Identification of the worst measures of synovial hypertrophy, synovial blood flow and joint damage among small-, medium-A and large-sized joints,” *Ultrasound in Medicine and Biology*, vol. 43, no. 6, pp. 1141-1152, 2017. [Online]. doi: <https://doi.org/10.1016/j.ultrasmedbio.2017.01.021>.
- [47] H. Nieminen, T. Ylitalo, J. P. Suuronen, K. Rahunen, A. Salmi, S. Saarakkala, R. Serimaa, and E. Haeggstrom, “Delivering agents locally into articular cartilage by intense mhz ultrasound,” *Ultrasound in Medicine and Biology*, vol. 41, no. 8, pp. 2259-2265, 2015. [Online]. doi: <https://doi.org/10.1016/j.ultrasmedbio.2015.03.025>.

- [48] S. Y. Kawashiri, T. Suzuki, Y. Nakashima, Y. Horai, A. Okada, A. Nishino, N. Iwamoto, K. Ichinose, K. Arima, M. Tamai, H. Nakamura, T. Origuchi, M. Uetani, K. Aoyagi, K. Eguchi, and A. Kawakami, "Synovial inflammation assessed by ultrasonography correlates with mri-proven osteitis in patients with rheumatoid arthritis," *Rheumatology*, vol. 53, no. 8, pp. 1452-1456, 2014. [Online]. doi: <https://doi.org/10.1093/rheumatology/keu034>.
- [49] Y. Wu, D. Jiang, J. Duan, X. Liu, R. Bayford, and A. Demosthenous, "Towards a high accuracy wearable hand gesture recognition system using eit," *IEEE International Symposium on Circuits and Systems (ISCAS)*, pp. 1-4 2018. [Online]. doi: <https://doi.org/10.1109/ISCAS.2018.8351296>.
- [50] S. A. Santos, C. C. Wembers, K. Horst, R. Pfeifer, T. P. Simon, H. C. Pape, F. Hildebrand, M. Czaplík, S. Leonhardt, and D. Teichmann, "Monitoring lung contusion in a porcine polytrauma model using EIT: an application study," *Physiological Measurement*, vol. 38, no. 8, pp. 1542-1560, 2017. [Online]. doi: <https://doi.org/10.1088/1361-6579/aa7985>.
- [51] Y. Zhang, R. Xiao, "Advancing hand gesture recognition with high resolution electrical impedance tomography," *UIST*, pp. 843-850, 2016. [Online]. doi: <https://doi.org/10.1145/2984511.2984574>.
- [52] D. J. Matthies, S. T. Perrault, B. Urban, and S. Zhao, "Botential: Localizing on-body gestures by measuring electrical signatures on the human skin," *International Conference on Human-Computer Interaction with Mobile Devices and Services*, pp. 207-216, 2015. [Online]. doi: <https://doi.org/10.1145/2785830.2785859>.
- [53] Y. Zhang and C. Harrison, "Tomo: Wearable, low-cost, electrical impedance tomography for hand gesture recognition," *UIST*, pp. 167-173, 2015. [Online]. doi: <https://doi.org/10.1145/2807442.2807480>.
- [54] J. Podlipská, A. Guermazi, P. Lehenkari, J. Niinimäki, F. W. Roemer, J. P. Arokoski, P. Kaukinen, E. Liukkonen, E. Lammentausta, and M. T. Nieminen, "Comparison of diagnostic performance of semi-quantitative knee ultrasound and knee radiography with MRI: Oulu knee osteoarthritis study," *Scientific reports*, vol. 6, no. 22365, 2016. [Online]. doi: <https://doi.org/10.1038/srep22365>.
- [55] F. Simeone, C. Gill, A. Taneja, M. Torriani, and M. Bredella, "Glenohumeral position during ct arthrography with arthroscopic correlation: optimization of diagnostic yield," *Skeletal Radiology*, vol. 46, no. 6, pp. 769-776, 2017. [Online]. doi: <https://doi.org/10.1007/s00256-017-2613-x>.

- [56] J. Avery, T. Dowrick, M. Faulkner, N. Goren, and D. Holder, "A versatile and reproducible multi-frequency electrical impedance tomography system," *Sensors*, vol. 17, no. 280, pp. 1-20, 2017. [Online]. doi: <https://doi.org/10.3390/s17020280>.
- [57] S. Hong, J. Lee, J. Bae, and H. J. Yoo, "A 10.4 mw electrical impedance tomography soc for portable real-time lung ventilation monitoring system," *IEEE Journal of Solid-State Circuits*, vol. 50, no. 11, pp. 2501-2512, 2015. [Online]. doi: <https://doi.org/10.1109/JSSC.2015.2464705>.
- [58] B. Cambiaghi, O. Moerer, N. K. Szikszay, T. Mauri, A. Just, J. Dittmar, and G. Hahn, "A spiky pattern in the course of electrical thoracic impedance as a very early sign of a developing pneumothorax," *Clinical Physiology and Functional Imaging*, vol. 38, no. 1, pp. 158-162, 2018. [Online]. doi: <https://doi.org/10.1111/cpf.12385>.
- [59] G. Boverman, T. J. Kao, X. Wang, J. Ashe, D. Davenport, and B. Amm, "Detection of small bleeds in the brain with electrical impedance tomography," *Physiological Measurement*, vol. 37, no. 6, pp. 727-750, 2016. [Online]. doi: <https://doi.org/10.1088/0967-3334/37/6/727>.
- [60] F. Fu, B. Li, M. Dai, S. J. Hu, X. Li, C. H. Xu, B. Wang, B. Yang, M. X. Tang, X. Z. Dong, Z. Fei, and X. T. Shi, "Use of electrical impedance tomography to monitor regional cerebral edema during clinical dehydration treatment," *PLoS ONE*, 2014, pp. 1-15. [Online]. doi: <https://doi.org/10.1371/journal.pone.0113202>.
- [61] T. Mauri, N. Eronia, C. Turrini, M. Battistini, G. Grasselli, R. Rona, C. Volta, G. Bellani, and A. Pesenti, "Bedside assessment of the effects of positive end-expiratory pressure on lung inflation and recruitment by the helium dilution technique and electrical impedance tomography," *Intensive Care Medicine*, vol. 42, no. 10, pp. 1576-1587, 2016. [Online]. doi: <https://doi.org/10.1007/s00134-016-4467-4>.
- [62] J. Karsten, C. Grusnick, H. Paarmann, M. Heringlake, and H. Heinze, "Positive end-expiratory pressure titration at bedside using electrical impedance tomography in post-operative cardiac surgery patients," *Acta Anaesthesiologica Scandinavica*, vol. 59, no. 6, pp. 723-732, 2015. [Online]. doi: <https://doi.org/10.1111/aas.12518>.
- [63] M. Bodenstein, S. Boehme, S. Bierschock, A. Vogt, M. David, and K. Markstaller, "Determination of respiratory gas flow by electrical impedance tomography in an animal model of mechanical ventilation," *BMC Pulmonary Medicine*, vol. 14, no. 73, pp.1-11, 2014. [Online]. doi: <https://doi.org/10.1186/1471-2466-14-73>.
- [64] S. Lehmann, S. Leonhardt, C. Ngo, L. Bergmann, S. Schradling, K. Heimann, N. Wagner, and K. Tenbrock, "Electrical impedance tomography as posible guidance for individual positioning

- of patients with multiple lung injury,” *Clinical Respiratory Journal*, vol. 12, no. 1, pp. 68-75, 2018. [Online]. doi: <https://doi.org/10.1111/crj.12481>.
- [65] E. Ericsson, E. Tesselaar, and F. Sjöberg, “Effect of electrode belt and body positions on regional pulmonary ventilation- and perfusion-related impedance changes measured by electric impedance tomography,” *PLoS ONE*, pp. 1-14, 2016. [Online]. doi: <https://doi.org/10.1371/journal.pone.0155913>.
- [66] O. Radke, T. Schneider, E. Vogel, and T. Koch, “Effect of trigger sensitivity on redistribution of ventilation during pressure support ventilation detected by electrical impedance tomography,” *Anesthesiology and Pain Medicine*, vol. 5, no. 4, pp. 1-6, 2015. [Online]. doi: <https://doi.org/10.5812/aapm.27439v2>.
- [67] Organización Mundial de Salud. “Dispositivos médicos”. . [Online]. Available: https://www.who.int/medical_devices/definiciones/es/.
- [68] C. Shi, S. Boehme, A. Bentley, E. Hartmann, K. Klein, M. Bodenstein, J. Baumgardner, M. David, R. Ullrich, and K. Markstaller, “Assessment of regional ventilation distribution: Comparison of vibration response imaging (vri) with electrical impedance tomography (eit),” *PLoS ONE*, vol. 9, no. 1, pp. 1-8, 2014. [Online]. doi: <https://doi.org/10.1371/journal.pone.0086638>.
- [69] M. Bodenstein, S. Boehme, H. Wang, B. Duenges and K. Markstaller, “Hints for cyclical recruitment of atelectasis during ongoing mechanical ventilation in lavage and oleic acid lung injury detected by SpO₂ oscillations and electrical impedance tomography,” *Experimental Lung Research*, vol. 40, no. 9, pp. 427-438, 2014. [Online]. doi: <https://doi.org/10.3109/01902148.2014.944719>.
- [70] M. Arregui, E. Santos and F. Simini, “Test Bench to Validate Audio CODEC Kit as EIT Complex Voltage Measurement Circuit,” *IFMBE Proceedings*, vol. 60, pp. 134-136, 2017. [Online]. doi: https://doi.org/10.1007/978-981-10-4086-3_34.
- [71] S. A. Santos, A. Robens, A. Boehm, S. Leonhardt and D. Teichmann, “System Description and First Application of an FPGA-Based Simultaneous Multi-Frequency Electrical Impedance Tomography,” *Sensors*, vol. 16, no. 1158, pp. 1-21, 2016. [Online]. doi: <https://doi.org/10.3390/s16081158>.
- [72] V. Chitturi, N. Farrukh, V. Thiruchelvam, and T. K. Fei, “A Low Cost Electrical Impedance Tomography (EIT) for Pulmonary Disease Modelling and Diagnosis,” *The Second International Conference on Technological Advances in Electrical, Electronics and Computer Engineering (TAECE2014)*, pp. 83-89, 2014. [Online]. Available: <https://www.researchga>

te.net/profile/Natalie_Walker4/publication/261064294_TAECE2014_Proceedings/links/0f317533219a10c30d000000.pdf#page=86.

- [73] Y. Zhang, R. Xiao and C. Harrison, "Advancing Hand Gesture Recognition with High Resolution Electrical Impedance Tomography," *UIST*, pp. 843-850, 2016. [Online]. doi: <https://doi.org/10.1145/2984511.2984574>.
- [74] M. R. Islam and M. A. Kiber, "Electrical impedance tomography imaging using Gauss-Newton algorithm," *3rd International Conference On Informatics, ELECTRONICS & VISION*, pp. 1-4, 2014. [Online]. doi: <https://doi.org/10.1109/ICIEV.2014.6850719>.
- [75] Y. Cai, C. Ma, P. Zhang, and J. Liu, "A novel method to reconstruct central aortic pressure signal using dual-peripheral pressure waves," *4th IEEE International Conference on Information Science and Technology*, pp. 565-568, 2014. [Online]. doi: <https://doi.org/10.1109/ICIST.2014.6920541>.
- [76] M. Hadinia and R. Jafari, "An element-free galerkin forward solver for the complete electrode model in electrical impedance tomography," *Flow Measurement and Instrumentation*, vol. 45, pp. 68-74, 2015. [Online]. doi: <https://doi.org/10.1016/j.flowmeasinst.2015.04.011>.
- [77] A. F. Mamani, "Resonancia magnética nuclear (RMN) en odontología," *Revista de Actualización Clínica Investiga*, vol. 38, pp. 1892-1896, 2013. [Online]. doi: <http://www.revistasbolivianas.org.bo/pdf/raci/v38/v38a09.pdf>.
- [78] Y. Wang, F. Seguro, E. Kao, Y. Zhang, F. Faraji, C. Zhu, H. Haraldsson, M. Hope, D. Saloner, and J. Liu, "Segmentation of lumen and outer wall of abdominal aortic aneurysms from 3D black-blood MRI with a registration based geodesic active contour model," *Medical Image Analysis*, vol. 40, pp. 1 - 10, 2017. [Online]. doi: <https://doi.org/10.1016/j.media.2017.05.005>.
- [79] K. Petersen, S. Vakkalanka and L. Kuzniarz, "Guidelines for conducting systematic mapping studies in software engineering: An update," *Information and Software Technology*, vol. 64, pp. 1-18, 2015. [Online]. doi: <https://doi.org/10.1016/j.infsof.2015.03.007>.